

Interdisciplinary S2k Guideline: Sonography in Urogynecology

Short Version – AWMF Registry Number: 015/055

Interdisziplinäre S2k-Leitlinie: Sonografie im Rahmen der urogynäkologischen Diagnostik

Kurzfassung – AWMF-Register-Nummer: 015/055

Authors

R. Tunn¹, S. Albrich², K. Beilecke³, J. Kociszewski⁴, C. Lindig-Knopke³, C. Reisenauer⁵, N. Schwertner-Tiepelmann³, A. Kuhn⁶, V. Viereck⁷, V. Bjelic Radisic⁸, D. Kölle⁹, W. Umek¹⁰, W. Bader¹¹, O. Schwandner¹², R. Lange¹³

Affiliations

The affiliations are listed at the end of the article.



Deutschsprachige
Zusatzinformationen
online abrufbar unter:
[www.thieme-connect.de/
ejournals/toc/gebfra](http://www.thieme-connect.de/ejournals/toc/gebfra)

Bibliography

DOI <http://dx.doi.org/10.1055/s-0034-1383044>
Geburtsh Frauenheilk 2014; 74:
1093–1098 © Georg Thieme
Verlag KG Stuttgart · New York ·
ISSN 0016-5751

Correspondence

Prof. Dr. med. Ralf Tunn,
Chefarzt Klinik für
Urogynäkologie,
Koordinator Deutsches
Beckenbodenzentrum
St. Hedwig-Krankenhaus
Große Hamburger Straße 5–11
10115 Berlin
R.Tunn@Alexius.de
[http://www.deutsches-
beckenbodenzentrum.de](http://www.deutsches-beckenbodenzentrum.de)
<http://www.alexianer.de>

DGGG-Leitlinienssekretariat

Prof. Dr. med.
Matthias W. Beckmann,
DGGG-Leitlinienbeauftragter
Frauenklinik
Universitätsklinikum Erlangen
Universitätsstraße 21–23
91054 Erlangen
Tel.: 091 31-85-3 35 07/4 40 63
Fax: 091 31-85-3 39 51

Principal Author

Prof. Dr. med. Ralf Tunn (Berlin)

Contributing professional societies

1. German Society for Gynecology and Obstetrics
2. Study Group for Urogynecology and Plastic Pelvic Floor Reconstruction of the German Society for Gynecology and Obstetrics
3. Study Group for Urogynecology and Reconstructive Pelvic Floor Surgery, Austria
4. Study Group for Urogynecology and Reconstructive Pelvic Floor Surgery, Switzerland
5. Surgical Study Group for Coloproctology
6. Professional Association of Gynecologists in Germany
7. German Society for Ultrasound in Medicine

Note

The long version, including the complete list of references and the guideline report, can be viewed on the AWMF website (www.awmf.org).

1 General Recommendation

Pelvic floor sonography is currently the gold standard in gynecology for the morphological diagnosis of incontinence and of functional disorders of the pelvic floor. X-ray examinations and MRI of the pelvic floor are much less common nowadays, and these examinations are usually only done to investigate more complex issues which cannot be adequately evaluated with ultrasonography.

Diagnostic ultrasonography should be done both perioperatively and after surgery for urinary incontinence or prolapse to evaluate complications. Sonography also provides useful biofeedback and can be used to assess the patient's progress after conservative treatment.

A review of recent international literature shows that, in the majority of studies, morphological diagnoses are obtained with sonography. A number of different methods are used for investigation and evaluation, which can make it difficult to compare the findings of different studies. While in previous years introital sonography and perineal ultrasound were the preferred 2D imaging methods used for diagnosis, more recent studies have focused on the use of 3D imaging methods. The basic principle, which applies to both approaches, is that metric assessments are secondary to descriptive evaluations as an important constituent of urogynecological diagnostics. Both methods are useful, particularly to assess complications after surgery for urinary incontinence and prolapse procedures, and both procedures have an important role to play in understanding and managing complications.

2 Investigation Techniques

Standard diagnostics should include 2D imaging. The choice of where to insert the probe and whether to use 2D or 3D imaging depends on the availability of ultrasound units and probes. In principle, three different methods can be used for ultrasound investigation:

1. endosonographic applications: vaginal ultrasound, endo-anal sonography,
2. external applications: perineal/introital/abdominal ultrasound,
3. a combination of the two methods, as described by J. Kociszewski (Hagen) who refers to this approach as “pelvic floor sonography”.

In perineal sonography the ultrasound frequency is generally 3.5–5 MHz while the ultrasound frequency used in introital sonography is 5–9 MHz.

3 Imaging

The following structures and organs, germane to incontinence and prolapse disorders, can be imaged with ultrasound: the bladder, the urethra and symphysis, the vagina, the uterus and the recto-uterine pouch, the rectum, the anal sphincter and the pelvic floor musculature. However, the images vary according to the method selected for imaging. The choice of ultrasound frequency significantly affects the quality of the images.

The 2D technology used in introital and perineal ultrasound provides a panoramic view of the lesser pelvis; it is considered the gold standard for the diagnosis of urinary incontinence.

4 Image Orientation

Recommended image orientation: cranial structures to be shown in the upper part of the image, caudal aspects in the lower part of the image; ventral views to be shown on the right and dorsal ones on the left.

These recommendations on image orientation should be followed when images are used in publications and official statements. In routine gynecological investigations, however, doctors can continue to use their preferred approach to facilitate orientation.

DEGUM (German Society for Ultrasound in Medicine), IUGA (International Urogynecological Association) and ICS (International Continence Society) recommend displaying cranial aspects in the upper part of urogynecological ultrasound images (● Fig. 1).

5 Evaluation Methods

Various methods to locate the internal urethral orifice have been assessed and their reproducibility evaluated. In perineal sonography the symphysis offers a stable structure which can be used as a reliable reference plane (central symphyseal axis) (● Fig. 2). In introital sonography, the imagined extension of the axis of the ultrasound probe serves as the reference plane. Both imaging methods showed good reproducibility. A reproducible anatomical structure provides the best reference axis. Funneling of the urethra, the location and mobility (rigid, mobile) of the urethra, and the position of the bladder floor (cystocele, descensus: vertical, rotatory, absent) act as qualitative parameters, although these and other terms such as hypermobility of the bladder neck, overcorrection after colposuspension, and kinking of the urethra are descriptive appellations and not precise definitions.

It is usually not possible to obtain a complete image of the symphysis with introital sonography or vaginal sonography. The lower edge of the symphysis is used as a point of reference in both methods (● Fig. 3).

The 3D method additionally shows the horizontal plane which can be used to evaluate the levator ani muscle.

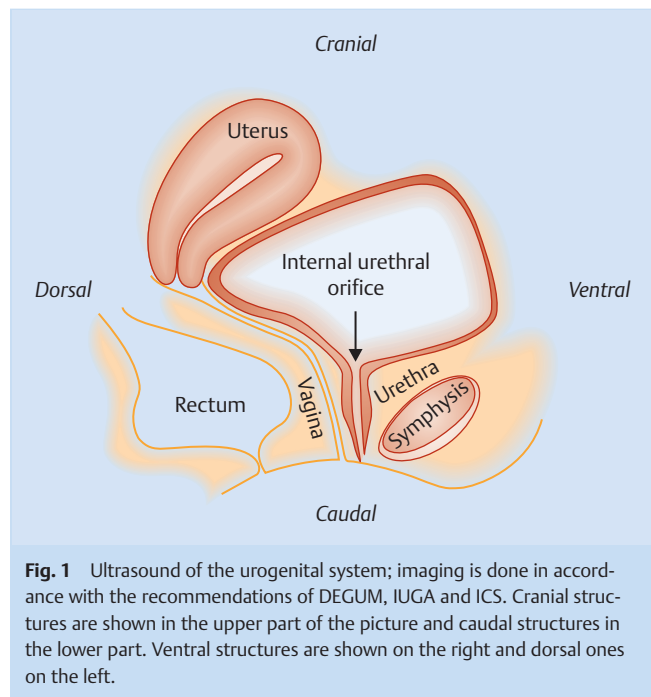


Fig. 1 Ultrasound of the urogenital system; imaging is done in accordance with the recommendations of DEGUM, IUGA and ICS. Cranial structures are shown in the upper part of the picture and caudal structures in the lower part. Ventral structures are shown on the right and dorsal ones on the left.

6 Patient Position

The examination can be carried out with the patient lying on a gynecological examination couch as the patient's position has only a limited effect on the results of the examination.

The measurement of quantitative parameters has shown that the internal urethral orifice is somewhat lower when patients are standing up, the posterior urethrovesical angle is bigger and funneling can be detected more easily. But overall, these measured differences are only slight and of no importance for the clinical evaluation as long as all images used for measurement are taken in the same position.

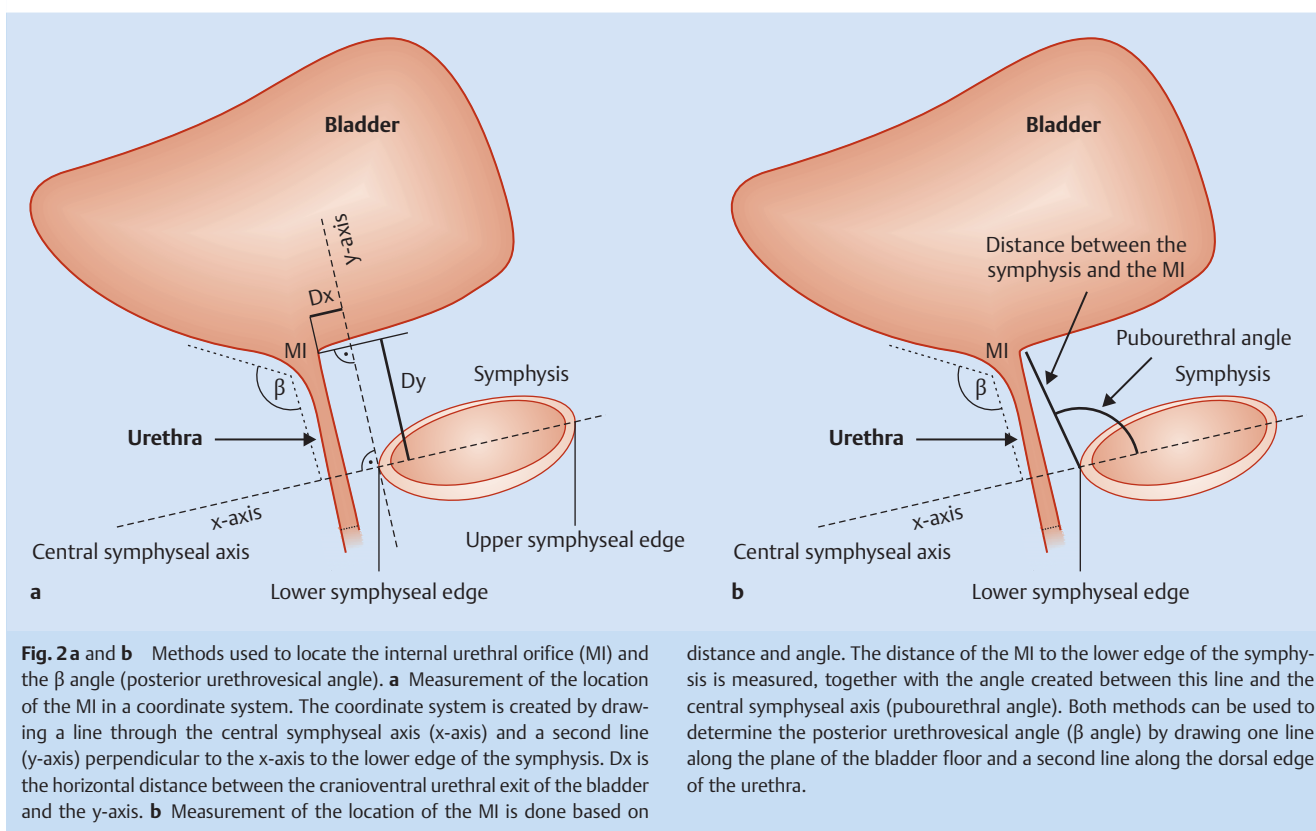
7 Bladder Filling

Bladder volume has only a limited impact on the measurement of distance and angles.

The bladder neck is more mobile when the bladder is empty, but detection of the bladder neck funnel is easier when the volume of bladder urine is larger. Examinations should be carried out when the bladder is filled with around 300 ml of urine. This corresponds to the volume of urine commonly used for urodynamic testing. The use of standardized bladder volumes permits a comparison of pre- and post treatment findings.

8 Results Influenced by Probe Manipulation

When carrying out examinations, examiners should exert the minimum pressure necessary on the ultrasound probe. Differences in the contact pressure of the ultrasound probe can change the measured results (retrovesical angle and location of the internal urethral orifice).



9 Functional Tests

Functional tests consist predominantly of incontinence and provocation tests, which are an integral part of any differential morphological diagnosis.

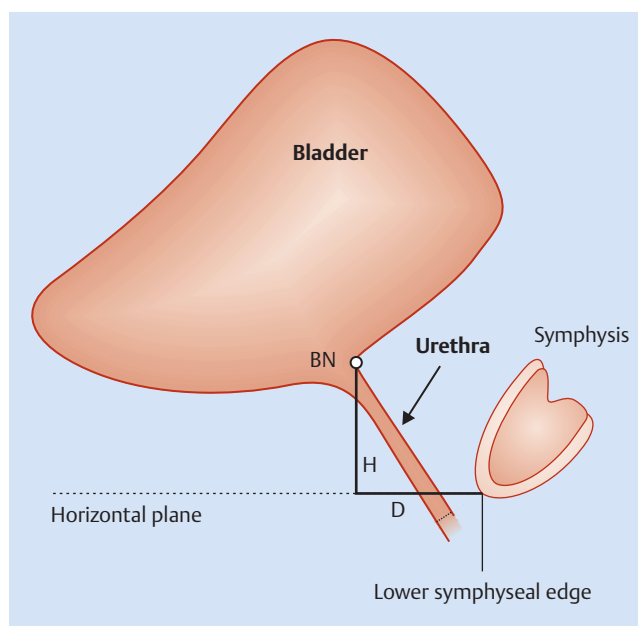
Sonography should be done in all four functional states: at rest, during straining, during coughing and during contraction of the pelvic floor. Measurement during straining is more useful to quantify bladder neck mobility than measurement during coughing. In clinical practice, visual biofeedback can be used to show the patient the elevation of the bladder neck during contractions.

10 Clinical Evaluation of Ultrasound Findings

10.1 Ultrasound findings for urinary stress incontinence

Urogynecological ultrasound performed prior to surgery for urinary incontinence can detect “clinically occult” risk factors. Examination must include sonographic measurement of urethral length, mobility of the urethra, and assessment of the height of the vaginal sulcus. Detection of changes to the proximal urethra (funneling), avulsion defects of the levator ani, or periurethral masses (e.g. urethral diverticula) complete the preoperative ultrasound diagnosis. These ultrasound parameters can influence the outcome of incontinence surgery. Such ultrasound findings are not only useful when selecting the appropriate surgical method, they are also important for tape placement. If such defects go unrecognized, they may become contributory factors for postoperative failure and/or postoperative complications.

Conservative treatment has long used rehabilitative ultrasound to provide biofeedback in physiotherapy. Under medical or physiotherapeutic guidance patients learn the correct way to tighten



or relax their muscles. Ultrasound can also be used during pelvic floor training (e.g. straining) to demonstrate incorrect muscular contractions.

10.2 Ultrasound diagnosis of overactive bladder

In patients with an overactive bladder, ultrasound investigation should be done first to exclude potential morphological causes such as cystocele, periurethral mass (e.g. diverticulum) or bladder wall mass, and examination should additionally include the measurement of bladder wall thickness. A symmetric bladder wall thickness of > 5 mm is often associated with the symptoms of an overactive bladder.

10.3 Ultrasound diagnosis of urogenital prolapse

Pelvic floor sonography is useful to differentiate between different prolapse defects. Ultrasound is used to determine the type of cystocele defect in the anterior compartment (central and lateral defect). Ultrasound offers as good images of enteroceles in the middle compartment and is as successful at differentiating between anterior rectocele and intussusception in the posterior compartment as defecography and can be used for primary diagnosis.

Anterior compartment

A central defect is present if the posterior urethrovesical angle forms an acute angle at rest or during straining. A lateral defect is present when the bladder neck drops below the lower edge of the symphysis while maintaining the urethrovesical angle.

Middle compartment

Ultrasound is of only limited use when determining the contents of an enterocele (sigmoid colon, small intestine).

In patients with a prolapsed uterus, it is important to assess the length of the cervix and the relationship between the body of the uterus and the cervix. Lengthening of the cervix can result in symptoms persisting after uterus-sparing treatment.

Posterior compartment

Perineal ultrasound or introital sonography can be used to demonstrate rectocele or intussusception in the posterior compartment.

11 Use of Ultrasound in Perioperative Assessment

Polypropylene meshes and tapes are clearly visible on ultrasound; other alloplastic and biological meshes are less visible. If the operation fails or the patient suffers from recurrence or symptomatic complications, ultrasonography should be done to assess the mobility of the bladder neck, residual urine and the position of the tape or mesh.

Urinary incontinence surgery

Sonography is indispensable to assess patients with recurrent urinary incontinence, postoperative voiding disorder, dysuria, dyspareunia, and de novo urge incontinence.

In addition to assessing tape position, tape configuration (flat, c-shaped, angled, parallel to the urethra) and the distance between tape and urethra in the sagittal plane (the latter information is particularly important if there is a suspicion of intramural or intraluminal tape position), transversal plane images can provide important information for diagnosis and further postopera-

tive management. It should be noted that obstructive tape complications are more common if the distance between tape and urethra is < 3 mm.

Ultrasonography can be used to assess the position and mobility of the bladder neck and the posterior urethrovesical angle after colposuspension. A possible correlation between urge incontinence and voiding disorders based on corresponding measurements is still being controversially discussed. Recurrent urinary urge incontinence after colposuspension has been correlated with postoperative persistent hypermobility and urethral funneling.

Prolapse surgery

Introital or endovaginal sonography can be used to determine the location and configuration of the mesh in prolapse surgery. Imaging along the sagittal plane can detect both recurrence of prolapse and avulsion of the apical anchorage of the mesh.

The main limitation of ultrasound assessment of mesh placement is the evaluation of apical mesh elements as these are often difficult or even impossible to visualize – unless prolapse has recurred, causing the cranial part of the mesh to drop down.

Ultrasound evidence of avulsion of the puborectalis muscle is associated with a higher risk of recurrence of prolapse after placement of an anterior transobturator mesh.

Mesh exposition cannot usually be identified visually on sonography. However, indications of mesh folding at the exposition sites may be detectable with both 2D and 3D ultrasonography.

12 Endo-anal Sonography

Endo-anal sonography is considered the gold standard for the detection of defects of the anal sphincter, but images have no clear correlation to functionality of the sphincter apparatus.

Endo-anal sonography should depict both the internal and the external anal sphincter on three planes.

Indications for endo-anal sonography include anal incontinence, anal and rectal tumors, investigation of perianal pain/suspicion of endometriosis, and preoperative and postoperative evaluation of the integrity of the sphincter complex in anal sphincter reconstruction.

The examination should start at the level of the U-shaped loop of the puborectalis muscle (level I); the probe should be moved in a caudal direction, starting from the cranial aspect. This will show the three anatomically defined levels of the anal canal (the deep [pars profunda], superficial [pars superficialis], and subcutaneous portions [pars subcutanea] of the anal canal).

Imaging should additionally depict the subepithelium, internal anal sphincter, the longitudinal musculature, and the external anal sphincter. Ultrasound examination should include the evaluation of thickness, symmetry, continuity and echogenicity.

The following pathologies have been described for the internal anal sphincter (IAS):

- ▶ IAS > 3.5 mm is considered pathological at all ages,
- ▶ IAS > 5 mm: hereditary myopathy,
- ▶ localized thickening; e.g. leiomyomas,
- ▶ IAS < 2 mm: muscle atrophy, anal incontinence, trauma, birth,
- ▶ interruption of the IAS: trauma, birth.

The following pathologies have been described for the external anal sphincter (EAS):

- ▶ loss of continuity indicates abnormality,
- ▶ partial or complete muscle avulsion,

- ▶ changes in echogenicity:
 - ▶ hematomas,
 - ▶ calcifications,
 - ▶ sphincter atrophy.

If resources are available, other ultrasound examinations can also be carried out to evaluate the sphincter apparatus.

13 Determination of Residual Urine

Ultrasound is the method of choice to determine residual urine. A simple formula to determine residual urine is based on measurement of bladder volume (length × width × depth of the bladder × correction factor 0.7). Measurement accuracy decreases with increasing bladder volume.

As the volume of residual urine varies over the course of the day, repeated measurements may be necessary.

14 Sonography of the Upper Urinary Tract

Ultrasonography is the primary diagnostic tool to evaluate the upper urinary tract.

Sonography of the upper urinary tract is indicated for:

- ▶ hematuria,
- ▶ neurogenic urinary incontinence,
- ▶ incontinence associated with significant residual urine,
- ▶ kidney and/or flank pain,
- ▶ severe urogenital prolapse to exclude hydronephrosis,
- ▶ suspicion of extraurethral urinary incontinence,
- ▶ suspicion of ectopic ureter or ureterovaginal fistula,
- ▶ children with LUTS, where necessary,
- ▶ urodynamic studies, if required.

It is recommended that preoperative and postoperative sonography of the upper urinary tract be carried out during urogynecological surgery.

15 Recommendations for Studies

To be able to compare different methods and scientific studies, the conditions within the studies must be similar, i.e., comparable intraabdominal pressure (rectal pressure) in dynamic imaging, comparable urine volumes, and comparable examination positions.

Publications on urogynecological sonography should include the following methodological information: examination position, medium used to fill the bladder and bladder fill volume, simultaneous pressure measurement, ultrasound transducer and ultrasound unit (type and manufacturer), ultrasound frequency, image orientation and examination method (introital, perineal, vaginal, abdominal or endo-anal sonography).

Ultrasound images should be shown using the following image orientation: the upper part of the image to correspond to the cranial aspect and the right side of the image to correspond to the ventral aspect.

16 3D and 4D Pelvic Floor Sonography

The most important additional information which can be obtained with 3D/4D sonography is acquired through imaging of the axial plane to examine the levator musculature with quantitative depiction of the size and shape of the urogenital and levator hiatus, both of which are associated with prolapse recurrence. The standard plane used for assessment is the axial plane at the level of the “plane of minimal hiatal dimensions”, which is orthogonal to the mid-sagittal plane. Measurement of the distance between the muscle insertion and the center of the urethral lumen (levator-urethra gap) is a reliable, reproducible method for the identification of levator defects, with a gap of > 25 mm defined as abnormal. Another method for the qualitative assessment of levator integrity is the detection of discontinuity of the echogenic puborectalis loop as shown in the “rendered volume” at the level of the plane of minimal hiatal dimensions during maximum pelvic floor contraction.

Quantitative measurement of the hiatal surface area is another 3D ultrasound parameter. A surface area of > 25 cm² at maximum Valsalva is defined as abnormal widening (“ballooning”).

3D ultrasound is also useful for the qualitative assessment of findings, for example to depict alloplastic slings, meshes and bulking agents.

17 Conclusion

Sonography is a useful complementary examination in urogynecology. It is used for functional-morphological documentation as part of the descriptive diagnosis. The variations in normal pelvic floor morphology and functionality mean that it can be difficult to make a distinction between “healthy” and “pathological”.

The cornerstones for a reliable urogynecological diagnosis are patient history, clinical examination, urodynamic testing, and imaging.

The validity of the guideline has been approved by the Board of the DGGG [German Society for Gynecology and Obstetrics] and the DGGG Guidelines Commission in December 2013. The guideline will remain valid until March 31st, 2017.

Conflict of Interest

See [Table 1](#).

Affiliations

¹ Senior Consultant, Klinik für Urogynäkologie, Koordinator Deutsches Beckenbodenzentrum, St. Hedwig-Krankenhaus, Berlin

² Universitätsmedizin Mainz, Mainz

³ St. Hedwig-Kliniken Berlin, Berlin

⁴ Ev. Krankenhaus Hagen, Hagen

⁵ Universitätsfrauenklinik Tübingen

⁶ Inselspital Bern, Bern, Switzerland

⁷ Kantonsspital Frauenfeld, Frauenfeld, Switzerland

⁸ Med. Universität Graz, Graz, Austria

⁹ BKH Schwaz, Schwaz, Austria

¹⁰ Medizinische Universität Wien, Vienna, Austria

¹¹ Klinikum Bielefeld, Bielefeld

¹² KH Barmherzige Brüder Regensburg, Regensburg

¹³ Praxis Schweppenhausen, Schweppenhausen

To cite as: National German Guideline (S2K): Sonography and Urology, AWMF Registry No. 015/055. Geburtsh Frauenheilk 2014; 74: 1093–1098

Table 1

	Dr. Stefan Albrich	Prof. Dr. Werner Bader	Dr. Kathrin Beilecke	Prof. Dr. Vesna Bjelic Radisic	Dr. Jacek Kociszewski	Dr. Dieter Kölle	PD Dr. Annette Kuhn	Dr. Rainer Lange	Dr. Claudia Lindig-Knopke	Prof. Dr. Christl Reisenauer	Prof. Dr. Oliver Schwandner	Dr. Nadine Schwertmer-Tiepelmann	Prof. Dr. Ralf Tunn	Prof. Dr. Wolfgang Umek	Prof. Dr. Volker Viereck
1	no	yes	no	no	no	no	no	yes	no	no	yes	no	yes	no	no
	Consultancy work or working in an advisory capacity or paid employment for the scientific advisory board of a healthcare company (e.g. pharmaceuticals industry, medical devices industry), a commercial contract research organization or an insurance company														
2	yes	yes	yes	yes	yes	no	no	yes	no	yes	yes	no	yes	yes	no
	Fees for lectures and training or paid authorship or co-authorship on behalf of a healthcare company, a commercial contract research organization or an insurance company														
3	no	no	no	no	no	no	no	yes	no	no	no	yes	no	no	no
	Funding grant (external funding) for research projects or direct financing of employees of the institution by a healthcare company, a commercial contract research organization or an insurance company														
4	no	no	no	no	no	no	no	no	no	no	no	no	no	no	no
	Owner interest in pharmaceuticals/ medical devices (e.g. patent, copyright, sales license)														
5	no	no	no	no	no	no	no	yes	no	no	no	no	no	no	no
	Ownership of shares, stock, funds with a stake in a healthcare company														
6	no	no	no	no	no	no	no	yes	no	no	no	no	no	no	no
	Personal relationship to an authorized representative of a healthcare company														
7	yes	yes	no	yes	no	yes	no	yes	no	yes	yes	no	yes	yes	no
	Membership of specialist organization/professional association connected to development of guidelines, elected representative for the development of guidelines														
8	no	no	no	no	no	no	no	no	no	no	no	no	no	no	no
	Political, academic (e.g. affiliation to specific "school"), scientific or personal interests which could constitute a possible conflict of interest														
9	Universitätsmedizin Mainz	Klinikum Bielefeld	St. Hedwig-Kliniken Berlin	Med. Universität Graz	Ev. Krankenhaus Hagen	BKH Schwaz	Insel-spital Bern	Praxis Schwepenhäuser	St. Hedwig Kliniken Berlin	Universitäts-Frauenklinik Tübingen	KH Barmherzige Brüder Regensburg	St. Hedwig-Kliniken Berlin	St. Hedwig-Kliniken Berlin	Medizinische Universität Wien	Kantons-spital Frauenfeld